

The Proximal Opening Wedge Osteotomy: A Review of the Evidence and Technique

Troy S. Watson, MD,*† Mark S. Hsiao, MD,† Chris Harasym, DO,*
and John P. Walsh, DO†

Abstract: The treatment of symptomatic, moderate-to-severe hallux valgus deformities offers numerous challenges to the foot and ankle surgeon. Many surgical procedures have been described for the correction of metatarsus primus varus with moderate-to-severe hallux valgus deformity. For the larger deformity, surgeons typically turn toward a shaft or basilar osteotomy or opt for a Lapidus-type procedure. The proximal opening wedge osteotomy has become popular with the recent development of specifically designed, low-profile, opening wedge, proximal metatarsal systems. Despite initial success and popularity, a reported 3% to 11% recurrence rate has been described in the literature. In this paper, we review the evidence, our indications, contraindications, technique, and pearls for success. We believe that the proximal opening wedge osteotomy technique provides excellent correction, is technically reproducible, easy to perform, and should be an option in every surgeon's toolbox. As techniques continue to evolve, we have added a closing wedge or distal biplanar osteotomy in those cases presenting with an increased distal metatarsal articular angle, to better achieve an isometric correction of the first metatarsal and prevent a late recurrence.

Level of Evidence: Diagnostic Level V. See Instructions for Authors for a complete description of levels of evidence.

Key Words: hallux valgus, osteotomy, metatarsophalangeal joint, hallux valgus angle, intermetatarsal angle

(*Tech Foot & Ankle* 2021;20: 208–215)

HISTORICAL PERSPECTIVE

The treatments of hallux valgus deformities are not all equal. With > 100 surgical procedures described in the literature, no procedure is adequate to correct all bunion deformities. The treatment of moderate-to-severe deformity [hallux valgus angle (HVA), > 20 degrees; intermetatarsal angle (IMA), > 13 degrees] is challenging and considers the use of either a proximal metatarsal osteotomy or a metatarsocuneiform arthrodesis with a distal soft tissue procedure.¹ Numerous proximal osteotomies have been described, with each technique touted for its ability to correct deformities of various magnitude and each with its unique set of complications. These proximal osteotomies include the Scarf,^{2–4} crescentic,^{5,6} the Ludloff,^{7,8} the modified Mau,⁹ the chevron,^{10,11} the closing lateral wedge osteotomy,¹² and now, the proximal medial opening wedge (Figs. 1A–E).^{13–17} As surgeons, we continue to search for the ideal proximal osteotomy that is technically easy to perform, with a low complication rate, that allows for a solid construct,

accelerated postoperative rehabilitation, and early weight-bearing. With the introduction of numerous proximal metatarsal osteotomy plates, the technique for medial opening wedge osteotomy may be the ideal proximal osteotomy for correcting moderate-to-severe deformities.

Historically, little has been written about the proximal first metatarsal osteotomy. Several earlier studies reported excellent functional results while noting excellent correction and high patient satisfaction.^{13,14,18} These osteotomies were reported to correct average preoperative IMA of 15 to 18 degrees to 8 to 11 degrees postoperatively. In adolescent bunions, the osteotomy resulted in high recurrence rates.^{19–21}

Scranton and Zuckerman, in 1984, summarized their review findings of bunion surgery in 50 feet in 31 adolescents. The authors intended to investigate the outcome of surgical correction of bunion deformity with primus varus and hallux valgus in a younger cohort. The 50 surgeries were performed by 8 surgeons utilizing 4 different surgical procedures: the McBride or modified McBride (8); the opening wedge proximal metatarsal osteotomy (5); the closing proximal metatarsal osteotomy (34); modified Lapidus procedure (3). The patient population included 3 males and 28 females with an average age of 14.0 years. The failure rate was 36%, with 17 patients having a recurrence of deformity. Twenty reoperations were performed for either deformity recurrence or hardware removal. Recurrence of the deformity was noted in 6 of the 8 McBride procedures, 3 of the 5 opening wedge osteotomy procedures, and 9 of the 34 closing proximal metatarsal osteotomy procedures. No deformity reoccurred in 3 modified Lapidus procedures, but 2 of the 3 required hardware removal. In general, the authors determined adolescents with bunion deformity require thorough discussion with the patient and parents before, during, and after surgery about the goals, risks, and complications of surgery due to the high complication rate seen in this series.

In one of the earliest studies looking at the opening wedge osteotomy and before plate specific hardware was designed for this indication, Limbird and colleagues reviewed their findings of the final angle after an opening wedge osteotomy. A McBride bunionectionomy was performed, and osteotomy performed 1.5 cm distal to the tarsometatarsal (TMT) joint keeping the lateral cortex intact. The use of iliac graft depended on the stability of the osteotomy site after the exostosis was shaped and placed in the site. Anteroposterior radiographs were used to compare the final IMA. The final average IMA was 8 degrees, which improved from an average of 15 degrees preoperatively. Overall, the authors concluded that an opening wedge osteotomy of the first metatarsal base is an effective procedure to treat metatarsus primus varus.

A meta-analysis to assess corrective power and complications of proximal first metatarsal osteotomies for hallux valgus deformity was published by Schuh et al²² including 62 primary studies and comprised of 2843 feet. The study aimed to compare the correction of the IMAs and HVAs and complications of proximal crescentic, Ludloff, proximal opening wedge, proximal closing wedge, proximal chevron, and a group of

From the *Department of Orthopaedic Surgery, Valley Hospital Medical Center; and †The Foot and Ankle Institute at Desert Orthopaedic Center, Las Vegas, NV.

The authors declare no conflict of interest.

Address correspondence and reprint requests to Troy S. Watson, MD, Department of Orthopaedic Surgery, Valley Hospital Medical Center, 2800 Desert Inn Road, Suite 100, Las Vegas, NV 89121.
E-mail: twatson@doicl.com.

Copyright © 2021 Wolters Kluwer Health, Inc. All rights reserved.

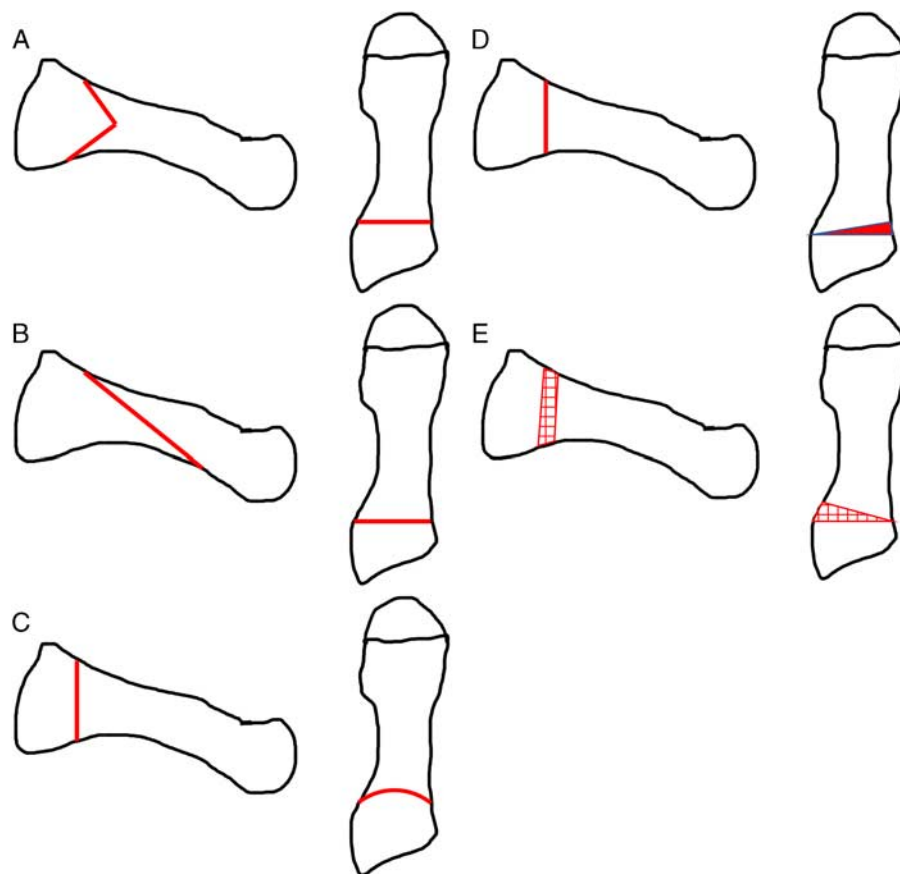


FIGURE 1. Anteroposterior and lateral views of various proximal osteotomies. A, Proximal chevron osteotomy. B, Ludloff osteotomy. C, Proximal crescentic osteotomy. D, Proximal closing wedge osteotomy. E, Proximal opening wedge osteotomy.

other proximal osteotomies not fitting into one of the above (Figs. 1A–E). The results of this study showed that proximal osteotomies achieved a correction of IMA of 8.1 degrees [proximal opening wedge osteotomy (PMOW) 7.2 degrees] and correction of HVA of 20.1 degrees (PMOW 19.6 degrees). A total of 534 complications (18.7%) occurred, with 364 (12.8%) categorized as major and 92 (3.2%) categorized as minor. Hallux varus and recurrence were the 2 most common complications representing 4.3% and 3.5% of the complications, respectively. Major complications in the PMOW group were 14.3%, but the breakdown of these complications was not provided. Of the techniques considered, the proximal chevron yielded overall the best angular correction and complication profile. In addition, their results demonstrated a higher corrective power of proximal osteotomies compared with meta-analysis data on diaphyseal osteotomies.

Glazebrook and colleagues performed a prospective, randomized trial comparing the PMOW with wedge-plate fixation with proximal chevron osteotomy for hallux valgus with increased IMA. They reported no significant differences in any of the patients' clinical outcome measurements between the 2 procedures. The PMOW lengthened, and the proximal chevron osteotomy shortened the first metatarsal. IMA improved significantly, from 14.8 to 9.1 after a PMOW and from 14.6 to 11.3 after a proximal chevron osteotomy ($P < 0.05$ for both). Operative times were found to be similar. It was determined that opening wedge and proximal chevron osteotomies have comparable radiographic and clinical outcomes for pain, satisfaction,

and function. PMOW was preferred by the orthopaedic surgeons involved in this study because it was subjectively less technically demanding.²³

INDICATIONS AND CONTRAINDICATIONS

As there are many choices in the treatment of bunion deformities, the surgeon must feel comfortable with the technique selected in each individual case. We do not perform the PMOW in all bunion deformities. Over the years, we have settled on using this procedure on patients presenting with a first-second IMA between 13 and 16 degrees and an HVA between 25 and 35 degrees (Figs. 2A–C). In this group of patients, we have seen excellent long-term results. As Iyer et al²⁴ demonstrated, failures may be seen in those with greater IMA and HVA and those with an increase in distal metatarsal articular angle (DMAA). They defined a recurrence of deformity as a hallux valgus drift of > 5 degrees. We have previously shown that almost all patients now fit into an opening wedge of 3.5 to 4.0 mm.²⁵ This will correct the IMA by 8 to 12 degrees, and we find that pushing the envelope past this point may result in recurrent deformity. Thus, we utilize the PMOW as a middle ground procedure: lesser deformities are treated with a distal chevron osteotomy or a mini-endobutton technique and deformities greater > 16 degrees IMA or HVA of ≥ 35 degrees are treated with a Lapidus-type procedure combined with a distal soft tissue procedure. If there is evidence of an increased DMAA then adding a biplanar closing wedge chevron osteotomy distally has helped us avoid some of the complications previously reported.^{24,25}

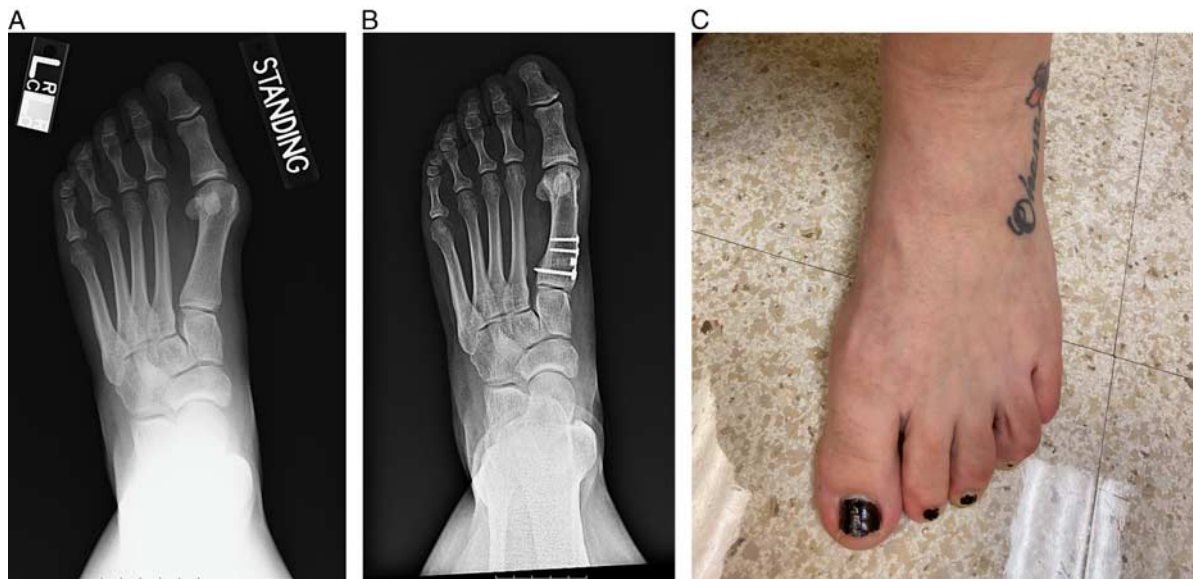


FIGURE 2. Ten-year follow-up of proximal opening wedge osteotomy without a distal biplanar chevron osteotomy. Although adding the distal osteotomy would likely have prevented some of the recurrences we are seeing, this patient remains very happy with her long-term outcome. A, Preoperative anteroposterior radiograph demonstrating 31 degrees hallux valgus angle and 15.5 degrees intermetatarsal angle. B, Ten-year follow-up anteroposterior radiograph showing slight recurrence and loss of hallux valgus angle now measuring 18.5 and 6.9 degrees intermetatarsal angle. C, Ten-year clinical follow-up image.

Contraindications to this technique are an arthritic first TMT joint, painful hallux metatarsophalangeal (MTP) joint arthrosis, and first-ray hypermobility. Relative contraindications are age above 65 years old, osteoporosis, inflammatory arthropathies, and neuromuscular disorders. Patients with an increased DMAA may still be treated with an opening wedge osteotomy but may also require concomitant procedures such as a distal biplanar chevron osteotomy.²⁵

We have also employed this technique to aid in revisions of previously failed bunion surgery. Specifically, we find this to be an ideal operative procedure in revising recurrent bunions in those that experienced iatrogenic shortening of the first ray.²⁶ We have revised several patients fitting this indication with great success (Figs. 3A–D).

PREOPERATIVE PLANNING

The preoperative assessment of a patient presenting with a bunion deformity begins with a thorough history and physical. Questioning about the onset of the deformity often reveals that patients are presenting with an adolescent bunion versus an acquired deformity later in life. Questioning about the presence of pain over the bunion deformity is important to avoid operating on patients without significant pain. Correcting a painless deformity can lead to postoperative pain, which was not present before surgery. In some cases, patients will present with lesser toe deformities or pain underlying the second metatarsal head that will require correction of the bunion. Also, a discussion of shoe wear modification should be had with all patients to make certain that they have trialed conservative care. Further history taking should address any underlying inflammatory arthropathy, such as lupus or rheumatoid arthritis, or any potential neuromuscular disease that can contribute to the formation of a bunion. These cases are typically better addressed with an MTP joint arthrodesis over other potential procedures.

Physical examination always starts with a standing examination of the patient looking specifically for postural abnormalities

that would include a flatfoot or cavus foot. In the weight-bearing position, you can assess for any cross-over toe deformity or pronation of the hallux. Following the weight-bearing examination, a seated inspection of the foot should begin. Calluses underlying the lesser MTP joints, if associated with pain, may be an indication of pathology that would need to be addressed at the time of surgery. Potential procedures to consider include shortening osteotomy or plantar plate repair. As stated previously, this could be the patients' presenting complaint. In these cases, we usually will operate on an asymptomatic bunion if we believe it is the contributing etiology for the lesser MTP pathology. Manipulation of the hallux MTP joint should be conducted to identify cases of concomitant hallux rigidus. Early rigidus can be addressed at the time of PMOW with a cheilectomy; however, appropriate preoperative counseling is necessary. The MTP arthrodesis may be indicated should pain with range of motion continue postoperatively. Assessing for the hypermobile first ray should be part of your examination as these patients are best treated with a Lapidus-type of correction to stabilize the first ray—many of our patients present with radiating pain over the medial aspect of the hallux. If a large medial eminence is present, compression of the dorsal cutaneous nerve may cause symptoms of radiating pain proximal and distal to the bunion. Documenting this preoperatively is recommended as most of these will dissipate with correction of the deformity and decompression of the superficial cutaneous nerve. Last, an examination of the lesser toes for hammertoes or other pathology should be documented so that these may be added to the index procedure if symptomatic.

Finally, after a careful history and physical are performed, a review of the weight-bearing radiographs of the foot should be completed. In all cases, we measure the HVA and the first and second metatarsal IMA. Examination for metatarsus adductus of the lesser metatarsals should be documented as this usually makes a PMOW difficult given the minimal space to correct the first ray. Typically, we are looking for patients with an HVA between 25 and 35 degrees and an IMA between 13

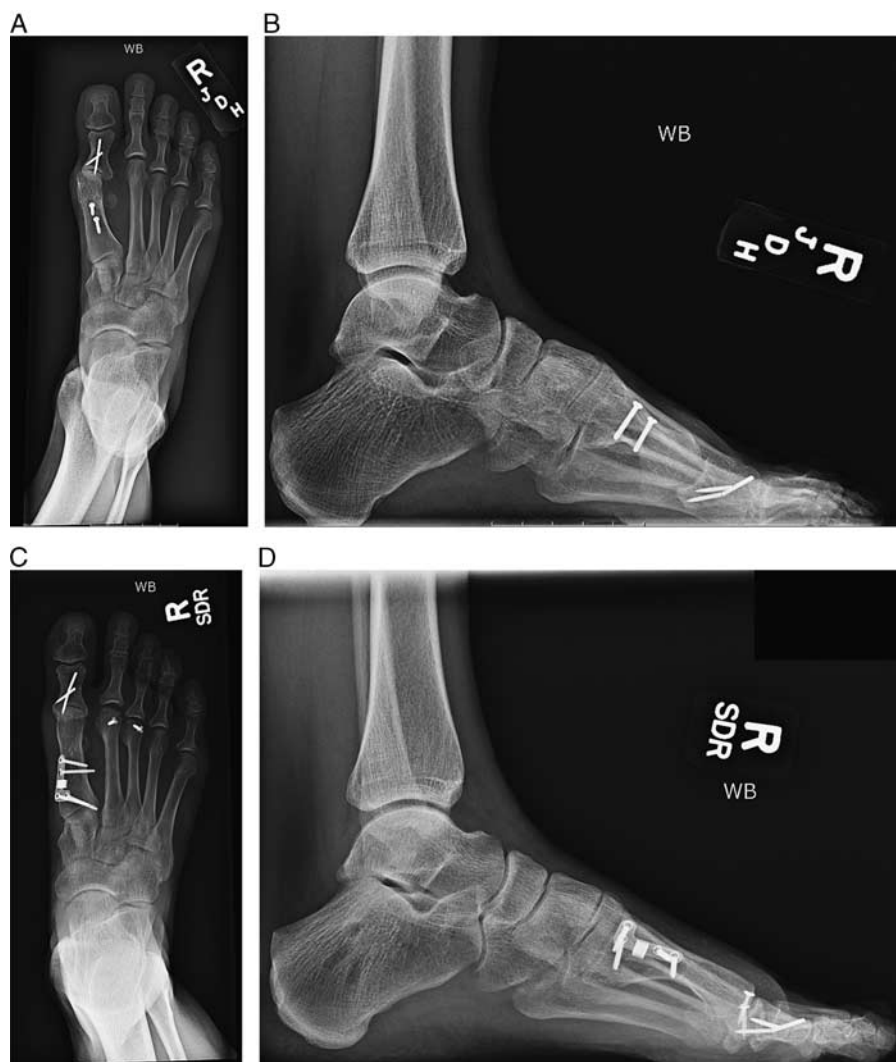

FIGURE 3. A and B, Anteroposterior and lateral preoperative radiographs show a previously failed scarf shaft osteotomy with a shortened and plantarflexed first ray. The patient has 21.5 degrees hallux valgus angle and 14.0 degrees intermetatarsal angle as a residual deformity with transfer metatarsalgia. C and D, Anteroposterior and lateral postoperative radiographs show postoperative correction of intermetatarsal angle and residual hallux valgus angle: 5.1 degrees intermetatarsal angle and 6.4 degrees hallux valgus angle. We felt this patient was an ideal candidate for the proximal opening wedge osteotomy given that we could gain length to her first metatarsal to combat her transfer metatarsalgia and improve alignment. At 1-year postsurgery, the patient remains very happy with her outcome.

and 16 degrees as ideal candidates for a PMOW. We do look for an increase in DMAA and, if present, will not hesitate to add a distal biplanar chevron osteotomy. However, we no longer measure this preoperatively but rather look at the joint intraoperatively and make a decision based on clinical appearance once the PMOW has been completed. Last, the lateral weight-bearing radiograph is examined for potential plantarflexion or dorsiflexion of the first metatarsal. We also look for any widening or gapping of the plantar aspect of the first TMT joint, which may be an indication of instability and likely will do better with a Lapidus-type procedure.

TECHNIQUE

Surgical success is conditionally dependent on proper patient selection, so we describe the technique with a patient for an illustrative example (Figs. 4A, B). The surgical technique

begins with a small dorsolateral incision located over the base of the great toe proximal phalanx. Dissection is carried down through the webspace, and the adductor tendon is identified as it attaches to the base of the proximal phalanx. Using a small hemostat, dissection under the tendon is completed, and transection of the tendon off the phalanx is completed. The tendon is then dissected sharply off the lateral aspect of the fibular sesamoid. The capsule between the metatarsal head and the fibular sesamoid is split with tenotomy scissors under direct vision. We no longer perform an aggressive lateral capsular release as we initially saw hallux varus developing with more aggressive releases.

Once this is completed, we then make one long medial incision extending from the mid-portion of the proximal phalanx and extending to the first TMT joint. We find this incision more cosmetically acceptable for patients, especially those that prefer to wear sandals. Once through the skin, the dorsal

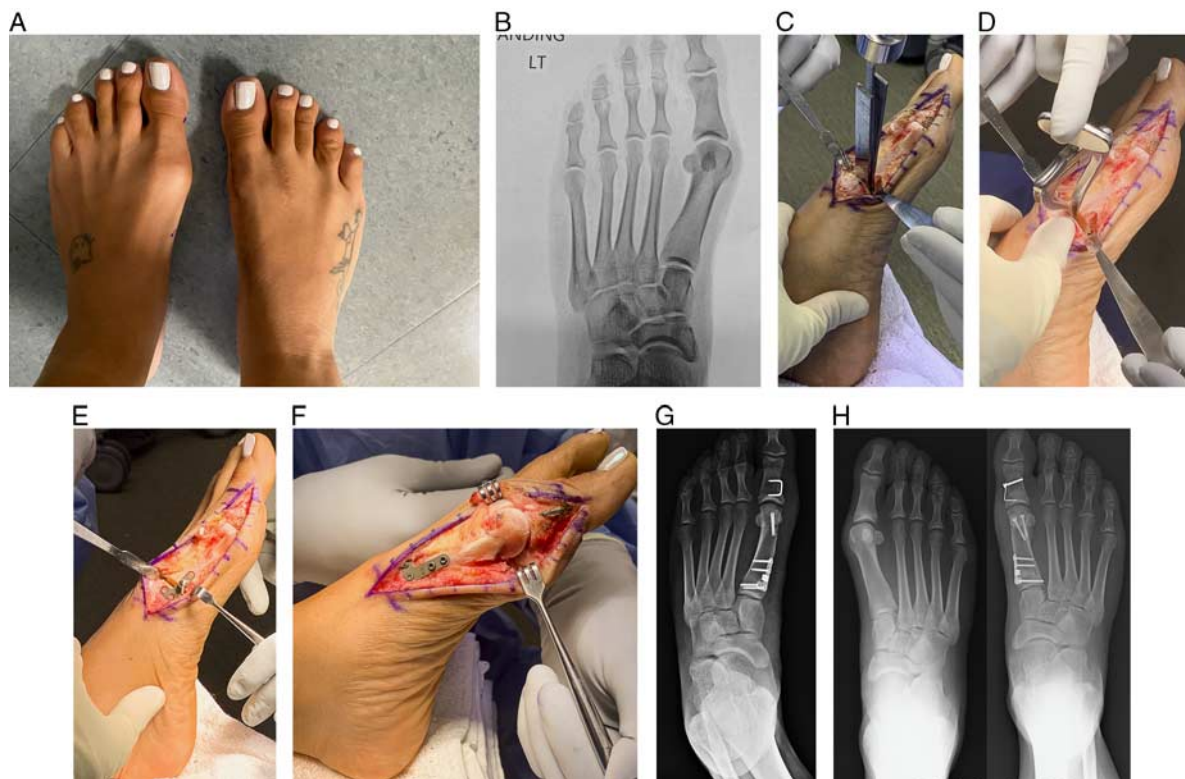


FIGURE 4. A, Clinical picture showing the 1-year postoperative result on the right foot and preoperative left foot. B, Preoperative left foot anteroposterior radiograph. Note an increase in distal metatarsal articular angle. C, After completing the oblique osteotomy at the base of the first metatarsal, the series of osteotomes are placed as shown and tapped into place, establishing an opening wedge. D, Use of the small spreader aids in opening the wedge. E, Provisional fixation of the plate to check correction with fluoroscopic imaging. F, Final construct with proximal opening wedge osteotomy with cancellous graft placed. Note the distal biplanar chevron osteotomy and an Akin proximal phalanx osteotomy. G, Final anteroposterior radiograph of the left foot. H, This patient had previously undergone the same procedure on the right foot 1 year prior. Preoperative anteroposterior and postoperative anteroposterior right foot depicted at 1 year postoperatively.

cutaneous nerve is dissected and protected with dorsal retraction throughout the procedure. A straight medial capsular incision is made to allow exposure of the large medial eminence. Resection of the medial eminence is then completed with a saw blade in line with the metatarsal shaft. Care is taken to resect minimal bone at the level of the joint to avoid instability leading to hallux varus. Saving the resected medial eminence can be helpful for harvesting autograft for the PMOW.

Once distal work is completed, attention is then turned proximally. Identification of the first TMT joint is made, and dissection of just enough of the medial metatarsal base is completed to allow for the osteotomy. Homan retractors are placed to protect dorsal and plantar structures. Using a short sagittal saw blade (measuring 1 cm in width), an oblique osteotomy is made at the base of the first metatarsal angled toward the proximal metatarsal. Typically, we start this bone cut about 15 mm distal to the first TMT joint. The osteotomy is typically made in an oblique fashion angling the cut proximally. The osteotomy is stopped short of the far cortex to allow for a hinged opening of the first metatarsal. The saw blade is perpendicular to the long axis of the bone and penetrates the bone to a depth of 10 to 12 mm. Light hand pressure, while cutting, will allow the surgeon to feel the far cortex and prevent overzealous violation of the lateral wall. Once the bone cut is completed, small osteotomes are used sequentially from largest to smallest until the wedge opens enough to place a small

distractor (Fig. 4C). Use a small spreader to open the wedge (Fig. 4D). On the basis of preoperative weight-bearing radiographs, the surgeon determines a starting point for plate fixation and trial. A 3.5 or 4.0 mm plate is typically applied to the medial bone off the rim on the plantar aspect of the metatarsal. We provisionally fix this with olive wires and then check fluoroscopic images simulating weight-bearing by pushing the foot into the base of the C-arm (Fig. 4E). If more correction is necessary, we typically increase by 0.5 mm increments. Again, the majority of patients now receive either a 3.5 or 4.0 mm wedge plate. We have seen 2 to 3 degrees correction of the IMA with each 1 mm of the opening wedge. Once the correct plate size is determined, fixation is completed with 2 screws distally and 2 screws proximally. Locking options are now available, but the authors typically use a nonlocking LPS set. Most commonly, shaft screws measure 16 mm, and proximal screws measure 20 to 22 mm in length. Care should be taken to avoid the placement of screws into the first TMT joint.

The bone graft is next harvested from the calcaneus through a small 1 cm incision, just distal and anterior to the distal fibula. Dissection is carried bluntly down to the bone where retractors are placed, and the use of a 7 mm reamer is used to obtain adequate graft for packing the opening wedge site. The correction and placement of hardware are next confirmed by fluoroscopic imaging. The DMAA is evaluated next to see if there is still clinically significant valgus stemming from

an increased DMAA. If the surgeon believes an increase in DMAA is a contributing factor, then a distal biplanar cut is performed to correct the head position and minimize the risk of recurrent deformity (Fig. 4F). Refer to Figure 4G for the durability of this patient's correction at 1-year follow-up. Alternatively, some surgeons prefer a closing wedge Riverdin osteotomy, and both should accomplish correction. The decision for the addition of an Akin closing wedge osteotomy is made based on the presence of hallux interphalangeus. Sometimes it is helpful in obtaining a bit more clinical correction. Finally, with the hallux held in a neutral position, capsular closure is completed with 2-0 Vicryl suture. Care is taken to correct any toe pronation if present with this soft tissue closure.

POSTOPERATIVE MANAGEMENT

A bulky gauze bunion strapping is placed in the operating room, and the extremity is fit and immobilized into a short CAM walking boot. Heel weight-bearing is allowed, and the dressings are changed at the first postoperative visit 3 to 5 days after surgery to a Coban and gauze wrap figure-of-eight dressing. We often close the skin with a 3-0 Monocryl suture and, therefore, do not need to remove sutures as they absorb after about 6 weeks. After 4 weeks of bunion strapping, a large toe separator is used with a sock, and patients are allowed full weight-bearing in the CAM boot. Postoperative radiographs should be obtained to make certain that no hallux varus is occurring and no loss of fixation at the PMOW. Most patients are in regular tennis shoes by 8 to 10 weeks, and fashionable shoes after 10 weeks are allowed.

Active and passive range of motion of the hallux MTP joint is started after the first postoperative visit. Patients are encouraged to perform a range of motion exercises in the dressings but are allowed to come out of the dressings if needed. In addition, if the difficulty is noted with a postoperative range of motion, then formal physical therapy is instituted.

RESULTS

Most proximal osteotomies have complications, including loss of fixation, first-ray shortening, dorsiflexion or plantarflexion malunion, nonunion, and overcorrection into varus as well as recurrent deformity. The ideal procedure would provide reliable and powerful correction with technical ease of completion. Since first publishing our experience with the PMOW in 2009, numerous publications have reported on its use.

In 2009, Shurnas and colleagues published the largest series to date of the PMOW. They retrospectively looked at 78 patients (84 feet) who underwent a PMOW with reliable, predictable correction and healing. There was only 1 nonunion, 1 delayed union, and no instances of hardware failure. There were 2 cases of hallux varus requiring revision surgery and 3 cases of recurrent hallux valgus requiring revision. Overall, 90% of patients reported good to excellent outcomes. There were no cases of overlengthening, but this finding may have been confounded. The lengthening secondary to PMOW is believed to be offset by concomitant distal biplanar chevron osteotomy shortening. We reported 2 to 3 degrees correction of IMA for every 1 mm of the opening wedge.¹⁵ Smith et al¹⁷ reported on 47 patients (49 feet) where they achieved a mean correction of 8 degrees for the IMA, correcting from an average of 16 degrees preoperatively to 8 degrees postoperatively. The average preoperative HVA was 28.4 degrees correcting to a final healed HVA of 8.6 degrees. Fourteen complications occurred, 6 of which involved mild hardware irritation, 4 nonunions, or delayed unions. Oravakangas et al²⁷ reported satisfactory mid-term results with a low complication rate in 31 patients (35 feet) with severe deformity undergoing PMOW. The mean IMA was corrected from 17 to 10

degrees. Two feet (5.7%) required revision surgery for recurrence. The potential instability of the first TMT did not seem to jeopardize the mid-term results.²⁷

Wukich reviewed 18 procedures (16 patients) demonstrating that PMOW with a modified McBride is a safe and useful surgical alternative for the correction of moderate-to-severe hallux valgus deformities with substantial metatarsus primus varus. Stabilization was achieved with a titanium fixation plate specifically designed for opening proximal osteotomies. No bone graft was used. The median IMA decreased by 9, the HVA decreased by 13.5, and the change in first metatarsal protrusion distance was +2.6 mm (range: -0.8 to 6.6 mm). The American Orthopaedic Foot and Ankle Society (AOFAS) Hallux Metatarsophalangeal-Interphalangeal post-operative scores were statistically significantly higher than the preoperative scores ($P < 0.001$). Complications included 2 (11.11%) recurrences and 1 (5.56%) case of deep vein thrombosis. Fourteen patients (16/18 feet, 88.89%) reported satisfaction with the surgical results.¹⁸

Saragas performed a retrospective study of 46 patients (64 feet) treated with PMOW using a low-profile plate in combination with a distal soft tissue release. The procedure was performed by a single surgeon over 18 months, and the same postoperative protocol was used in all the patients. HVA and IMA improved by a mean of 14.7 and 6.4 degrees, respectively. AOFAS forefoot scores improved from a mean of 51.3 to 86.8. The length of the first metatarsal increased by a mean of 2.3 mm but was not statistically significant. Complications included 5 patients who developed a hallux varus, one of which was symptomatic. There was 1 nonunion requiring a bone graft. It was shown that PMOW in combination with a distal soft tissue release and stable fixation using a low-profile plate was an effective method for correcting a moderate hallux valgus deformity.²⁸

Last, Nery et al²⁹ presented the results of 41 patients (70 feet) with moderate-to-severe hallux valgus, treated with the PMOW osteotomy, using 2 different screw and plate systems. They used the Darco BOW (DARCO International Inc., Huntington, WV) or the Arthrex LPS plate. Biplanar chevron and/or Akin osteotomy was also performed based on the magnitude of distal angles. Weight-bearing radiographs and AOFAS scores were used to evaluate each patient. They found that HVA, IMA, DMAA, and interphalangeal angles improved by a mean of 14, 8, 11, and 7 degrees, respectively. Sesamoid position improved in 79% of the feet. AOFAS score improved from a mean of 50 to 82. They determined that PMOW osteotomy is effective in correcting high-level hallux valgus deformities. While both systems of fixation were found to be effective, the addition of a distal procedure to the PMOW was recommended to correct distal angles.

Despite the initial popularity of the PMOW osteotomy with reported good outcomes,^{15,18,23,29} several studies have reported recurrences ranging from 3% to 11%.^{15,18,22,28} Iver et al²⁴ reported 11 of the 17 patients (64.7%) had evidence of recurrence of their hallux valgus deformity at final follow-up at an average of 2.4 years. These authors defined recurrence as a drift of ≥ 5 degrees of the HVA. They suggested that recurrence was seen in those patients with a larger preoperative HVA and DMAA and that this operation may be better suited in those patients with milder deformity and no increase in their DMAA. It did not appear that these authors attempted to correct the large DMAA in patients with a DMAA > 10 degrees at the time of the index procedure, which likely accounts for their high rate of recurrence. We concur with this sentiment and believe the ideal candidate has a preoperative IMA of 13 to 16 degrees and an HVA between 25 and 35 degrees. If an increased DMAA is present, a biplanar distal chevron osteotomy is often combined with the PMOW osteotomy to combat this deformity and prevent a recurrence. Siekmann and Watson recognized this fact and

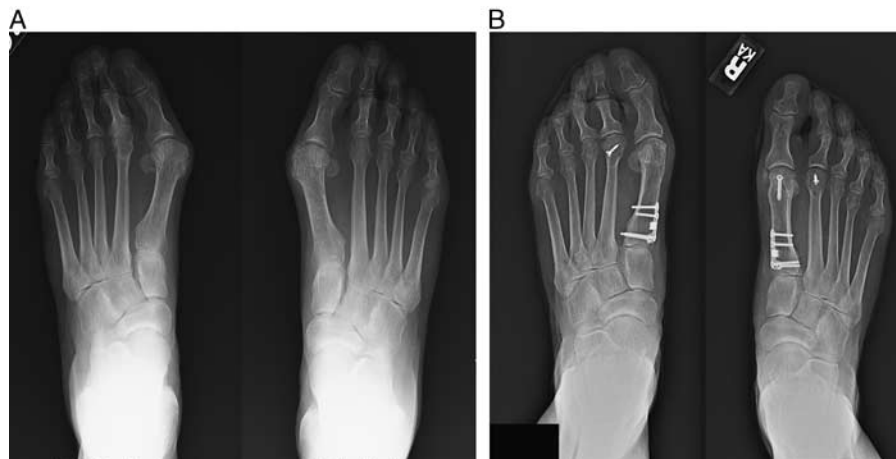


FIGURE 5. Preoperative and 9-year follow-up radiographs. A, Preoperative anteroposterior radiograph of the left foot demonstrating 36 degrees hallux valgus angle and 16.1 degrees intermetatarsal angle and preoperative anteroposterior radiograph of the right foot demonstrating 33 degrees hallux valgus angle and 15.4 degrees intermetatarsal angle. B, Nine-year follow-up anteroposterior of left foot demonstrates hallux valgus angle 21 degrees and intermetatarsal angle 6 degrees. Anteroposterior of right foot demonstrates hallux valgus angle 11.6 degrees and intermetatarsal angle 3.7 degrees. Although the patient remains very satisfied with her outcome bilaterally, a slight recurrence of the deformity is noted on the left side when compared with the right. This may illustrate the benefit of adding a distal biplanar chevron osteotomy to prevent this recurrence seen here on the left foot. The patient remains without symptoms bilaterally at this juncture.

published their results looking at the use of this double osteotomy to better correct larger deformities or those with increased distal angles. The first to second metatarsal IMA corrected from an average of 18.9 to 8.6 degrees postoperatively. The authors concluded that the double osteotomy has clear advantages over the isolated PMOW including potentially better correction especially in those patients with an increased DMAA (Figs. 5A, B).²⁵

A technique tip employed to improve correction is to use an oblique cut in the metatarsal. Han and colleagues compared the straight PMOW with a group undergoing an oblique PMOW. They found the group with an oblique PMOW had a greater radiographic and clinical correction. When performing an oblique osteotomy, the center of rotation of angulation is located more proximally and closer to the second metatarsal base than the straight osteotomy. Thus, the distance from the first to the second metatarsal decreases to a greater extent in an oblique osteotomy than in a straight osteotomy.³⁰

In conclusion, PMOW is a powerful technique that can be performed with technical ease, reproducibility, and thus, should still be part of a surgeon’s armamentarium, but meticulous attention to detail and addition of distal osteotomies may be required in select cases to prevent a recurrence.

COMPLICATIONS

The most frustrating complication to surgeons and patients alike is a recurrent deformity (Fig. 6). We believe that correctly selected patients, as discussed under the indications section, will help prevent some of these recurrences. As Iyer and colleagues discussed, failures of this procedure were in patients with larger HVA and those with larger DMAA. They did not perform the distal biplanar chevron that we advocate in these patients, and that may be the reason they saw a higher rate of failure. However, as in all bunion surgery, recurrent deformities can be seen. It is helpful to discuss this with patients as part of the preoperative informed consent. Initially, we did see cases of hallux varus, but this has, in large part, been eliminated by less medial eminence resection and a less aggressive lateral release. We have seen some cases of painful hardware, and all respond

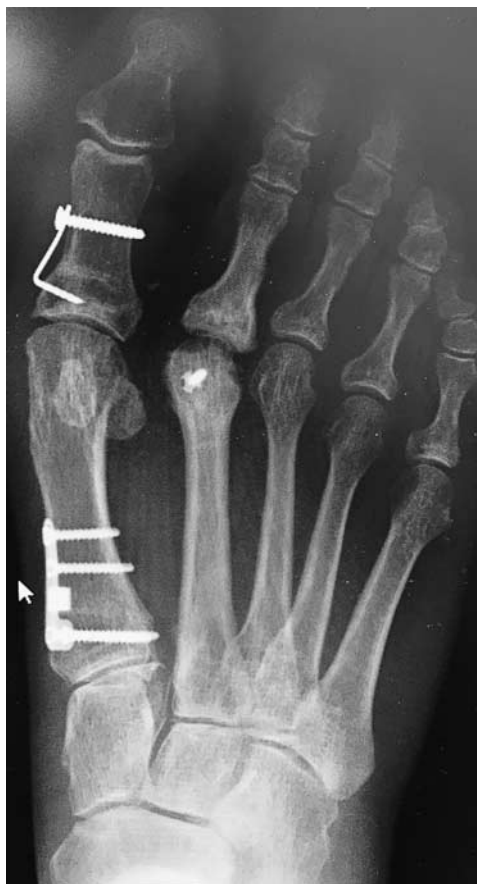

FIGURE 6. Anteroposterior radiograph showing a failure of proximal opening wedge osteotomy at 1.5 years postoperatively. Note the recurrence of hallux valgus and encroachment on the second toe requiring a revision.

to simply removing the hardware once the PMOW has healed adequately. One case of plantarflexion through the osteotomy was seen requiring a revision procedure. This can be avoided by checking your postoperative lateral radiograph for any signs of dorsiflexion or plantarflexion. The concern for joint stiffness has been reported for PMOW.³¹ In the senior author's experience, any postoperative stiffness experienced by patients has resolved with physical therapy. Prior kinematic gait investigation before and after surgery identified that a hallux valgus deformity imparted structural and functional problems to the kinematic chain. Subsequently, functional problems are unaddressed by surgery³² and may partially explain the resolution of symptoms with physical therapy.

FUTURE OF TECHNIQUE

Although this technique has fallen a bit out of favor, it remains a workhorse in my practice for those patients with the correct indications. We still find this operation technically easy to perform and with reliable outcomes. The corrections seen intraoperatively are maintained, and we now have patients with over 10 years of follow-up with maintained corrections. We have improved the technique by creating a closing wedge distally to create a more isometric correction of the first ray. Some hypothesize that this may eliminate overloading the hallux MTP joint, which in theory could cause hallux MTP arthritis.²⁵ While newer techniques have gained in popularity with rotational correction of the deformity, I would argue that not all bunion deformities require such a correction. We will continue to use this operative procedure for those bunions that fall somewhere in between needing a distal chevron osteotomy and those needing a Lapidus-type procedure.

REFERENCES

- Anderson R, Saltzman C. Hallux valgus. In: Coughlin M, ed. *Mann's Surgery of the Foot and Ankle 2, Volume 1*, 9th ed. St. Louis: Mosby; 2002:155–321.
- Miller JM, Stuck R, Sartori M, et al. The inverted Z bunionectomy: quantitative analysis of the scarf and inverted scarf bunionectomy osteotomies in fresh cadaveric matched pair specimens. *J Foot Ankle Surg.* 1994;33:455–462.
- Dereymaeker G. Scarf osteotomy for correction of hallux valgus. Surgical technique and results as compared to distal chevron osteotomy. *Foot Ankle Clin.* 2000;5:513–524.
- Kristen KH, Berger C, Stelzig S, et al. The SCARF osteotomy for the correction of hallux valgus deformities. *Foot Ankle Int.* 2002;23:221–229.
- Mann RA, Rudicel S, Graves SC. Repair of hallux valgus with a distal soft-tissue procedure and proximal metatarsal osteotomy. A long-term follow-up. *J Bone Joint Surg Am.* 1992;74:124–129.
- Coughlin MJ. Proximal first metatarsal osteotomy. In: Kitaoka H, ed. *Master Techniques in Orthopaedic Surgery: The Foot and Ankle*, 2nd ed. Philadelphia, PA: Lippincott Williams & Wilkins; 2002:71–98.
- Saxena A, McCammon D. The Ludloff osteotomy: a critical analysis. *J Foot Ankle Surg.* 1997;36:100–105; discussion 159–160.
- Bae S-Y, Schon LC. Surgical strategies: Ludloff first metatarsal osteotomy. *Foot Ankle Int.* 2007;28:137–144.
- Glover JP, Hyer CE, Berlet GC, et al. Early results of the Mau osteotomy for correction of moderate to severe hallux valgus: a review of 24 cases. *J Foot Ankle Surg.* 2008;47:237–242.
- Easley ME, Kiezbak GM, Davis WH, et al. Prospective randomized comparison of proximal crescentic and proximal chevron osteotomies for correct of hallux valgus deformity. *Foot Ankle Int.* 1996;17:307–316.
- Sammarco GJ, Brainard BJ, Sammarco VJ. Bunion correction using proximal chevron osteotomy. *Foot Ankle.* 1993;14:8–14.
- Nigro JS, Greger GM, Catanzariti AR. Closing base wedge osteotomy. *J Foot Surg.* 1991;30:494–505.
- Cooper MT, Berlet GC, Shurnas PS, et al. Proximal opening-wedge osteotomy of the first metatarsal for correction of hallux valgus. *Surg Technol Int.* 2007;16:215–219.
- Limbird TJ, DaSilva RM, Green NE. Osteotomy of the first metatarsal base for metatarsus primus varus. *Foot Ankle.* 1989;9:158–162.
- Shurnas PS, Watson TS, Crislip TW. Proximal first metatarsal opening wedge osteotomy with a low-profile plate. *Foot Ankle Int.* 2009;30:865–872.
- Watson TS, Shurnas PS. The proximal open wedge osteotomy for the correction of hallux valgus deformity. *Tech in Foot Ankle Surg.* 2012;11:168–174.
- Smith WB, Hyer CF, DeCarbo WT, et al. Opening wedge osteotomies for correction of hallux valgus: a review of wedge plate fixation. *Foot Ankle Spec.* 2009;2:277–282.
- Wukich DK, Roussel AJ, Dial D. Opening wedge osteotomy of the first metatarsal base: a technique for correction of metatarsus primus varus using a new titanium open wedge plate. *Oper Tech Orthop.* 2006;16:76–81.
- Bonney G, Macnab I. Hallux valgus and hallux rigidus; a critical survey of operative results. *J Bone Joint Surg Br.* 1952;34:366–385.
- Goldner JL, Gaines RW. Adult and juvenile hallux valgus: analysis and treatment. *Ortho Clin North Am.* 1976;7:863–887.
- Scranton PE Jr, Zuckerman JD. Bunion surgery in adolescents: results of surgical treatment. *J Pediatr Ortho.* 1984;4:39–43.
- Schuh R, Willegger M, Holinka J, et al. Angular correction and complications of proximal first metatarsal osteotomies for hallux valgus deformity. *Int Orthop.* 2013;37:1771–1780.
- Glazebrook M, Copithorne P, Boyd G, et al. Proximal opening wedge osteotomy with wedge-plate fixation compared with proximal chevron osteotomy for the treatment of hallux valgus: a prospective, randomized study. *J Bone Joint Surg Am.* 2014;96:1585–1592.
- Iyer S, Demetracopoulos CA, Sofka CM, et al. High rate of recurrence following proximal medial open wedge osteotomy for correction of moderate hallux valgus. *Foot Ankle Int.* 2015;36:756–763.
- Siekman W, Watson TS, Roggelin M. Correction of moderate to severe hallux valgus with isometric first metatarsal double osteotomy. *Foot Ankle Int.* 2014;35:1122–1130.
- Easley ME, Tryka H-J. Current concepts review: hallux valgus, part II: operative treatment. *Foot Ankle Int.* 2007;28:748–758.
- Oravakangas R, Leppilahti J, Laine V, et al. Proximal opening wedge osteotomy provides satisfactory midterm results with a low complication rate. *J Foot Ankle Surg.* 2016;55:456–460.
- Saragas NP. Proximal opening-wedge osteotomy of the first metatarsal for hallux valgus using a low-profile plate. *Foot Ankle Int.* 2000;30:976–980.
- Nery C, Ressio C, de Azevedo Santa Cruz G, et al. Proximal opening-wedge osteotomy of the first metatarsal for moderate and severe hallux valgus using low profile plates. *Foot Ankle Surg.* 2013;19:276–282.
- Han SH, Park EH, Jo J, et al. First metatarsal proximal opening wedge osteotomy for correction of hallux valgus deformity: comparison of straight versus oblique osteotomy. *Yonsei Med J.* 2015;56:744–752.
- Yi Y, Lee WC. Comparison of three-dimensional displacement among different metatarsal osteotomies. *Foot Ankle Clin.* 2018;23:193–203.
- Klugarova J, Janura M, Svoboda Z, et al. Hallux valgus surgery affects kinematic parameters during gait. *Clin Biomech (Bristol, Avon).* 2016;40:20–26.